



# THE 2<sup>nd</sup> INTERNATIONAL TRAUMA SYMPOSIUM Injuries of the Upper Extremity - from top to bottom



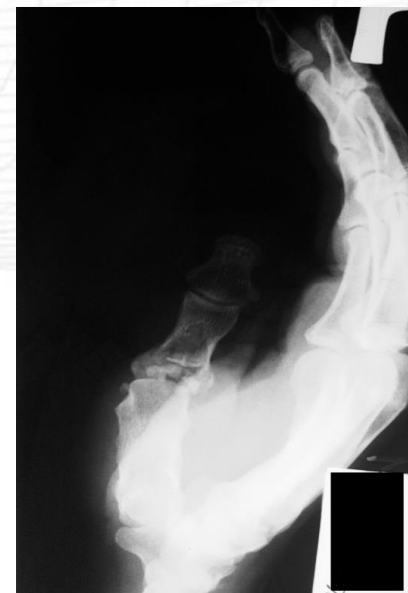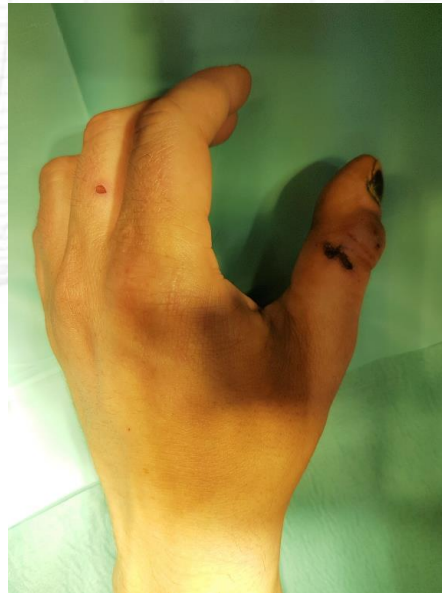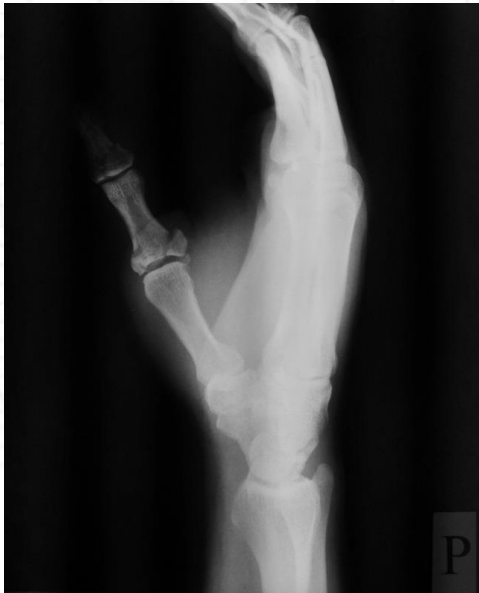## *The role of external fixators in the treatment of thumb fractures*

***Henryk Guzik, Damian Kusz***

**Department of Orthopedics and Traumatology Medical University of Silesia - Katowice  
Head of Department: Prof. dr hab. n. med. Damian Kusz**

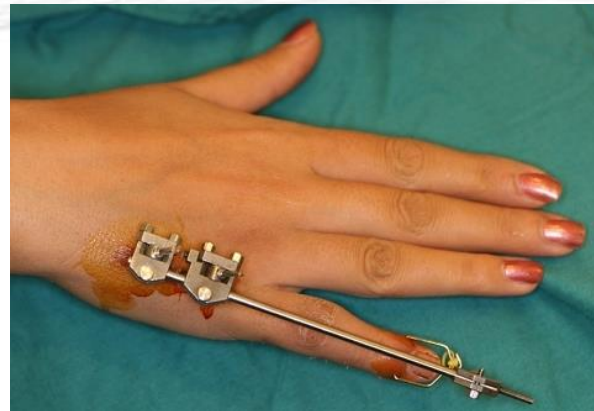
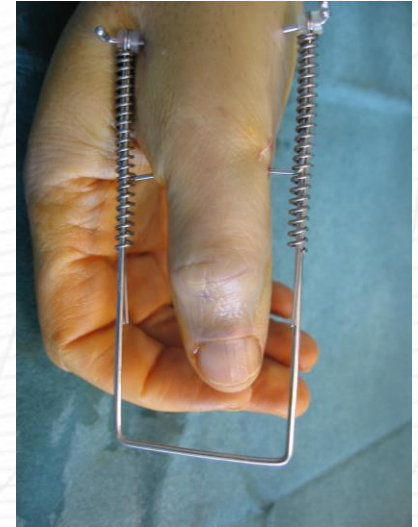# Introduction

- Comminuted, intra-articular thumb fractures, with extensive soft tissue injuries, are a serious medical problem, often difficult to treat by open stabilization with plate and screws or percutaneous stabilization with K wires.



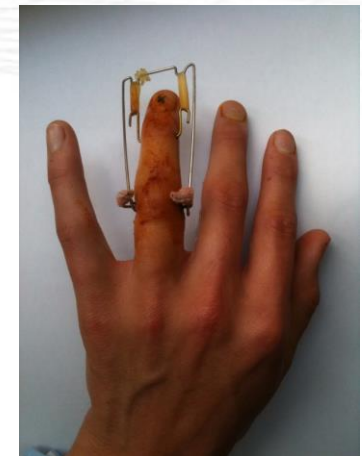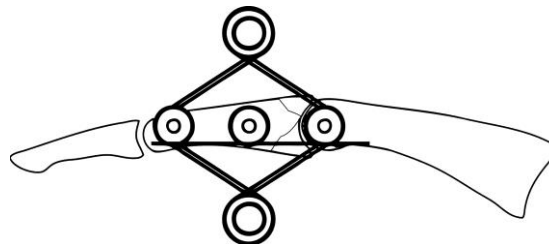
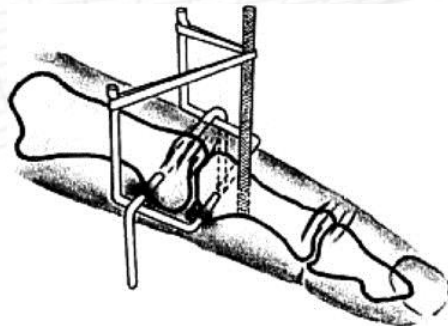
# Introduction

- Treatment outcomes depend on the effective stabilization of fragments, correct axial alignment of fragments and early motion.
- There are only few reports and publications about the described types of fractures in the thumb and methods of their treatment, in particular, comparing the available procedures.
- Dynamic distraction external fixation (DDEF) meets all these conditions.



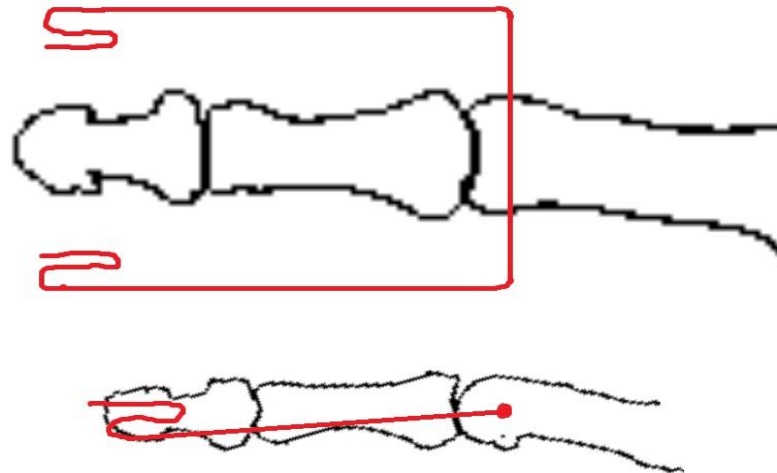
# Introduction

- Treatment with commercially available stabilizers it is not always possible due to their poor availability and high cost.
- The stabilizers made of inexpensive K wires, according to the principles set out, among others by Slade, Agee, Inanami, Suzuki or Allison, seems to be the most advantageous solution.
- The lack of articular surface reposition by ligamentotaxis may require additional open reduction and bone grafting, or additional percutaneous fixation with K wires.



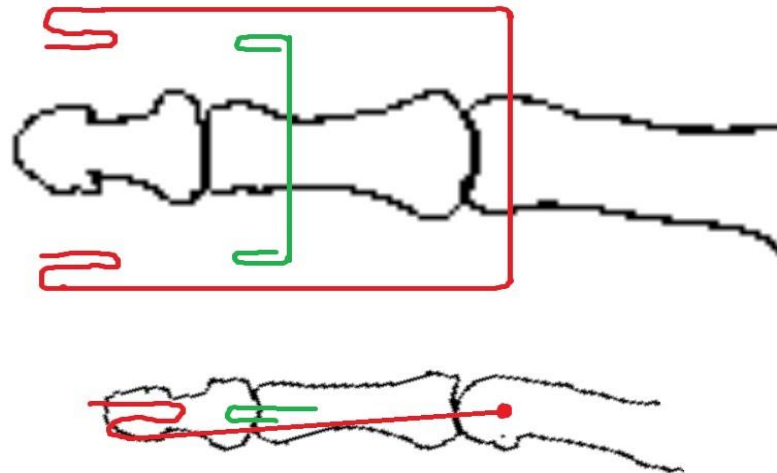
# Method

## Dynamic distraction external fixation by Slade



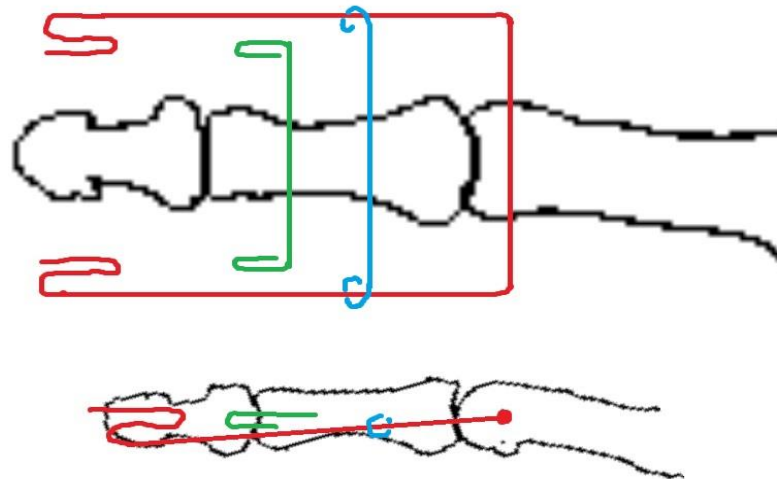
# Method

## Dynamic distraction external fixation by Slade



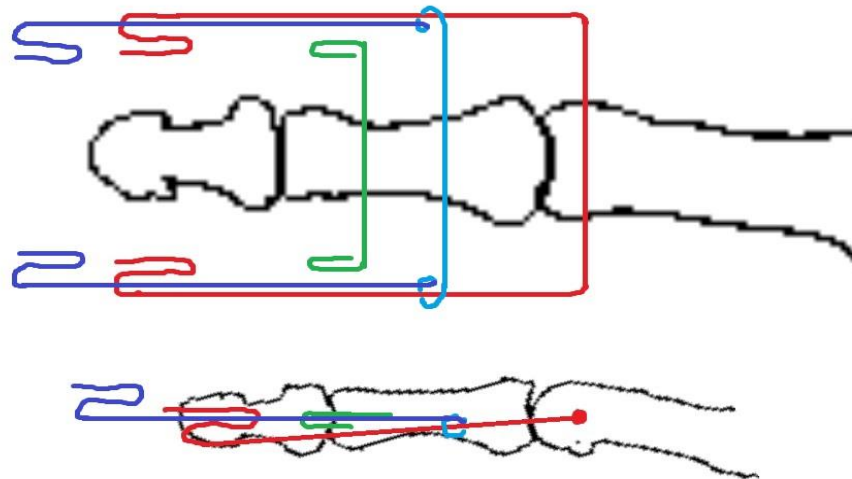
# Method

## Dynamic distraction external fixation by Slade



# Method

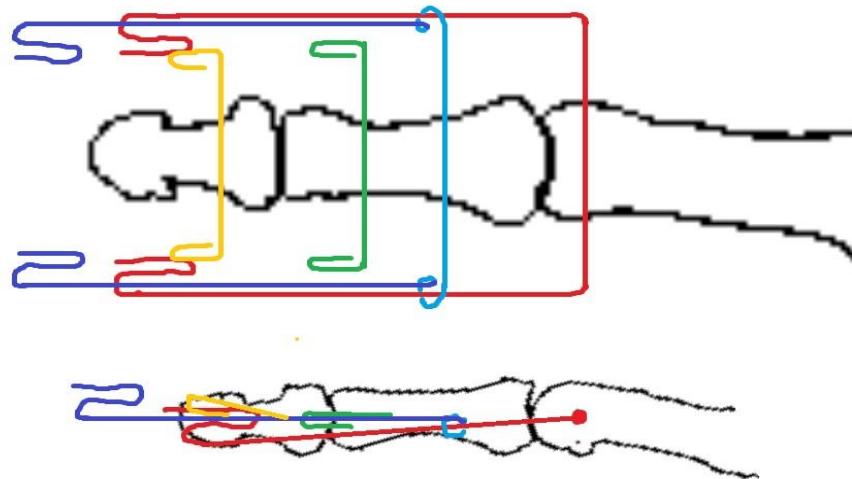
## Dynamic distraction external fixation by Slade





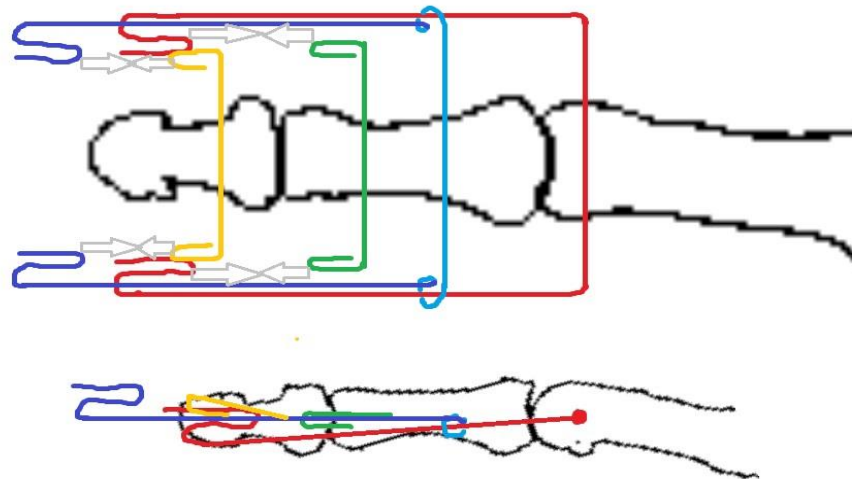
# Method

## Dynamic distraction external fixation by Slade

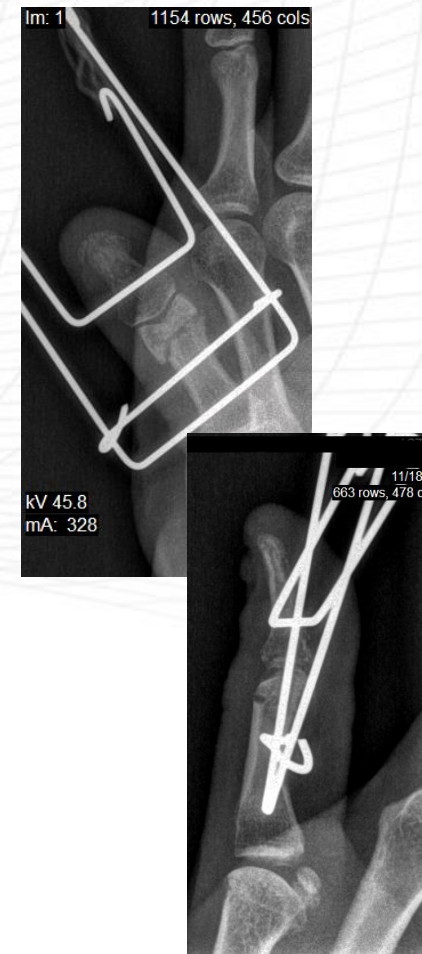
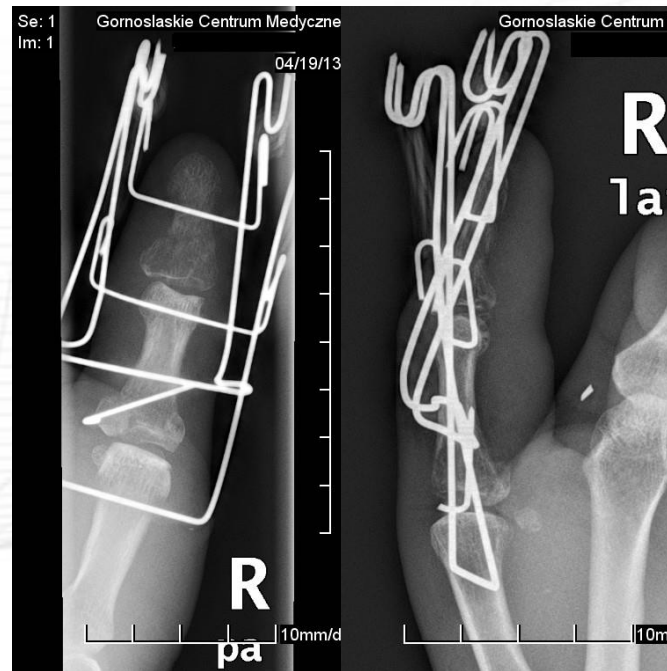
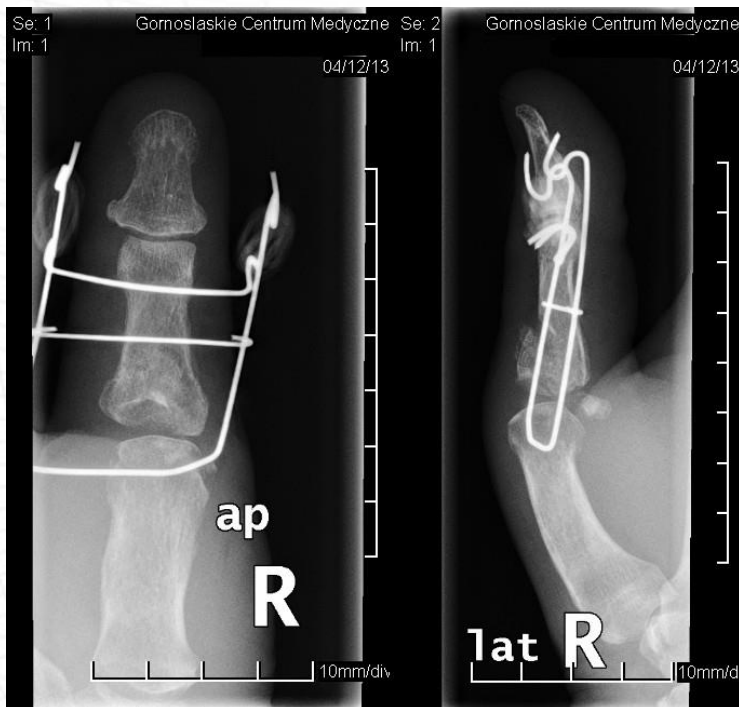

# Method

## Dynamic distraction external fixation by Slade

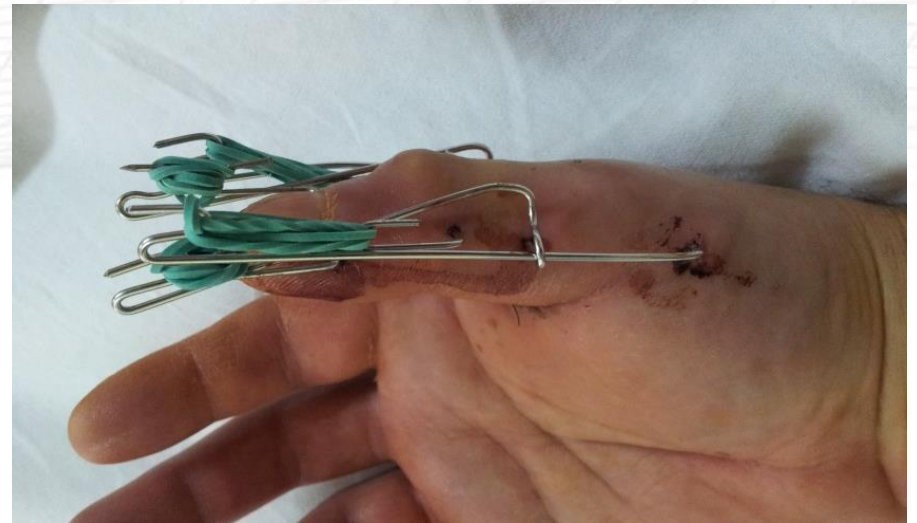
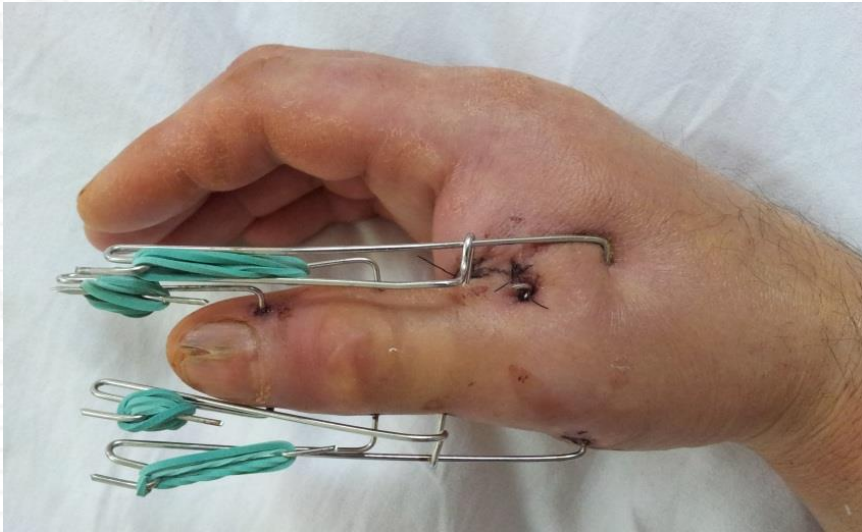
## Dynamic distraction external fixation by Slade



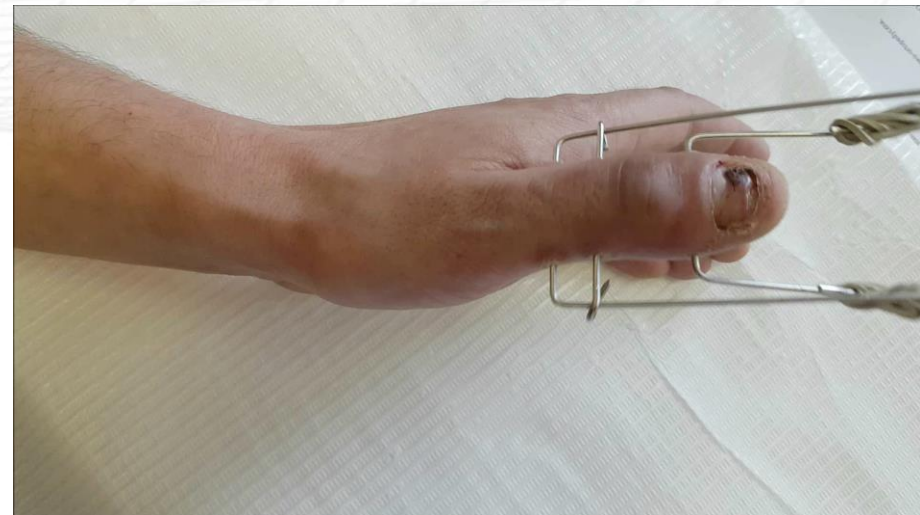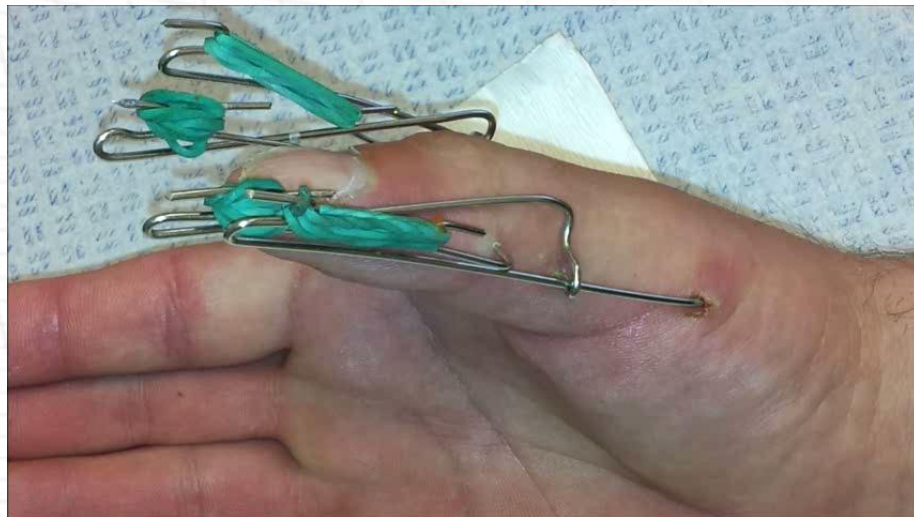# Method

## Dynamic distraction external fixation by Slade



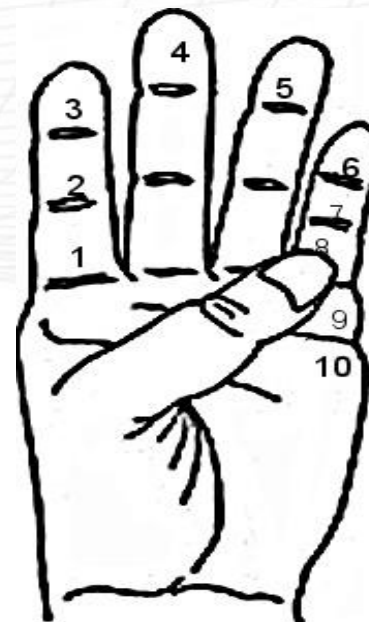# Method

Active motion were started from 2nd day after the surgery.



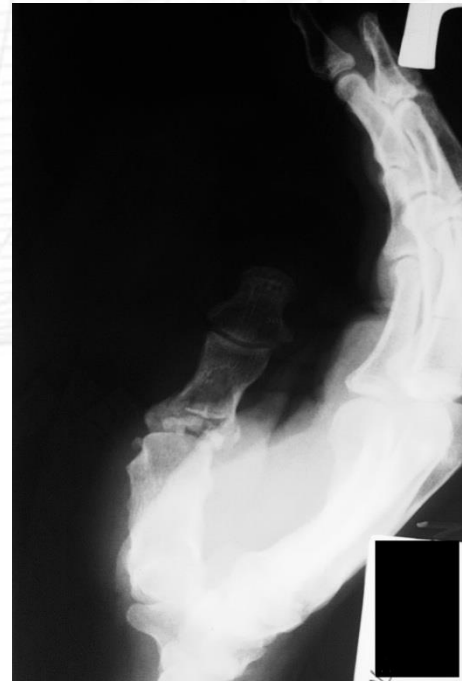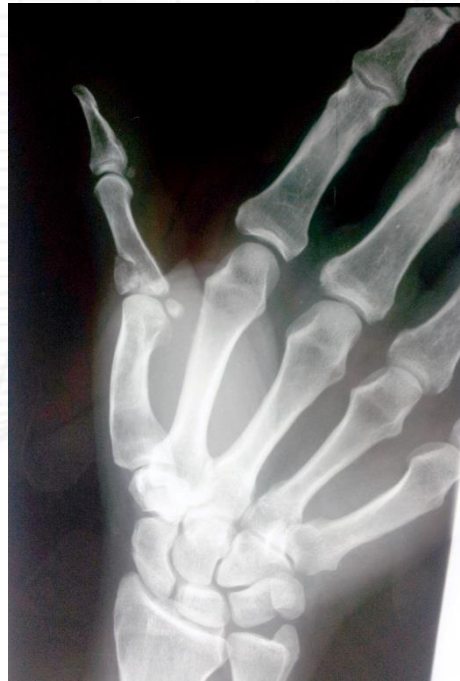# Method

- The fixator was removed in the outpatient settings five weeks after surgery.
- Then the process of rehabilitation continued - active and passive motion, diadynamics, whirlpool massage, magnetotherapy, laser therapy.
- We evaluated the result 5 months after bone union was achieved, using Kapandji test and the DASH questionnaire.

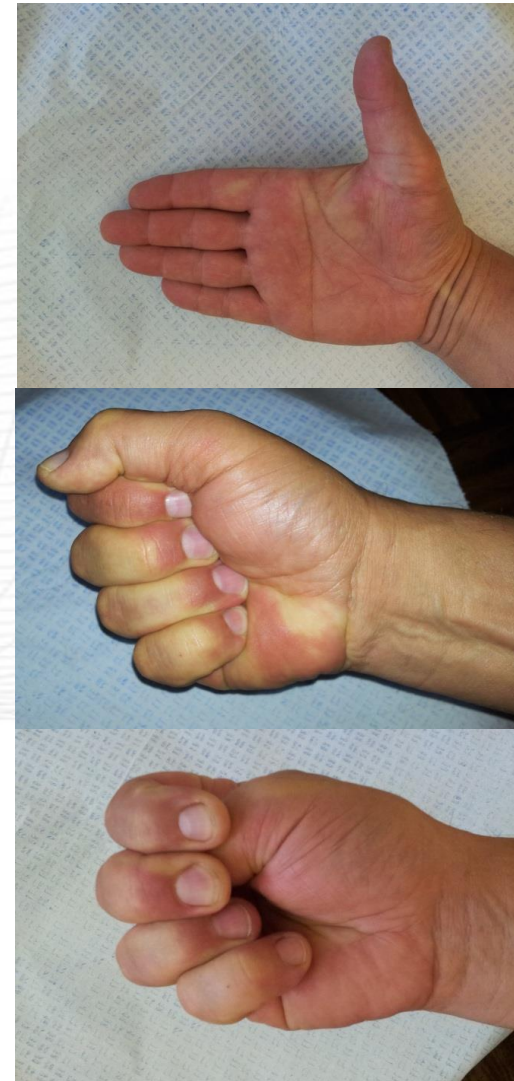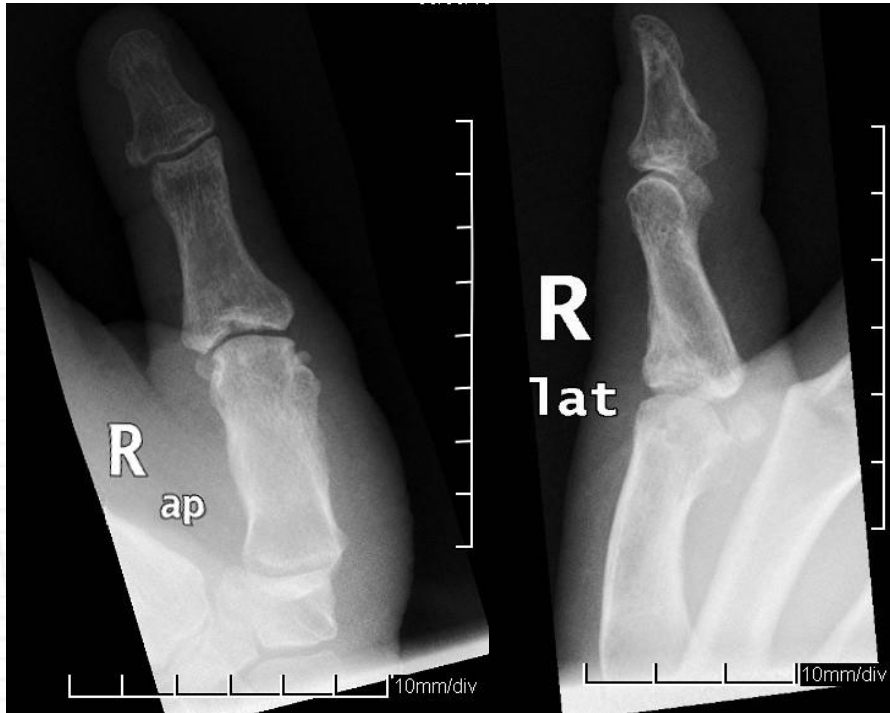


# Case 1

- Male, 58 years old, skiing accident – brain commotion, left proximal humerus fracture, comminuted intra-articular fracture of right thumb (base of proximal phalanx).



# Case 1

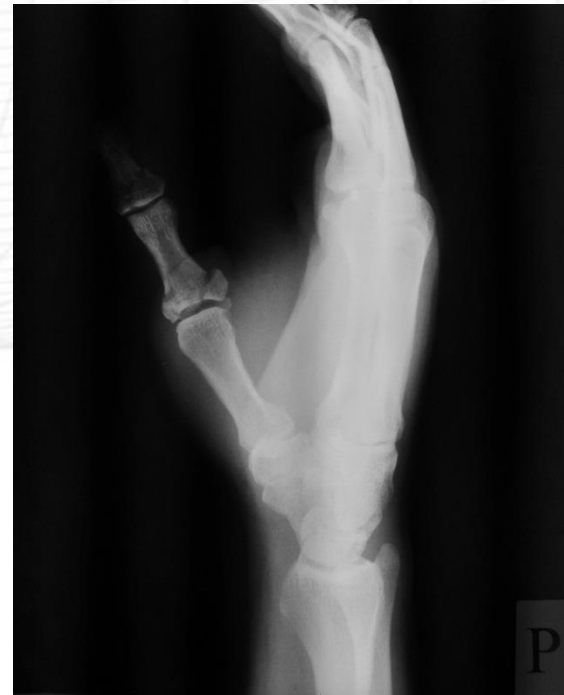
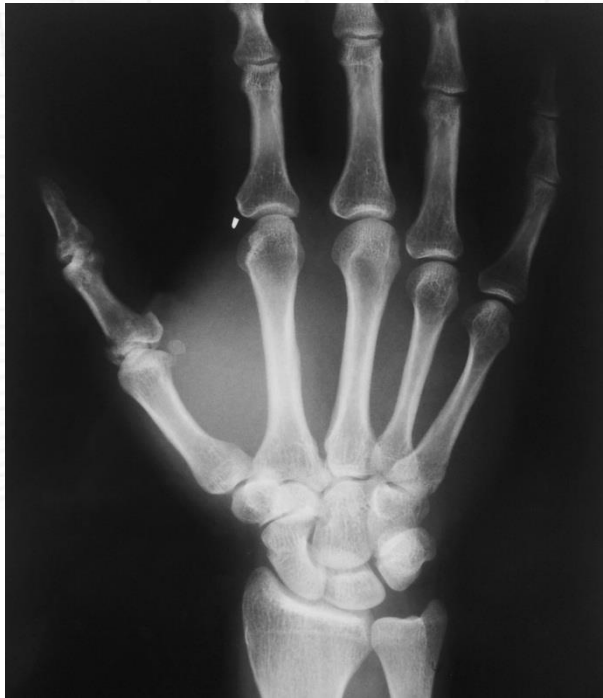
DASH questionnaire – 58 pkt.  
Kapandji test - 9

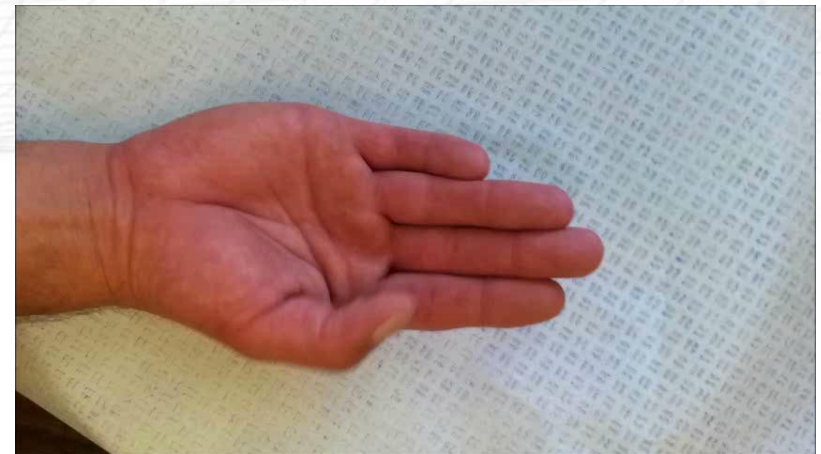
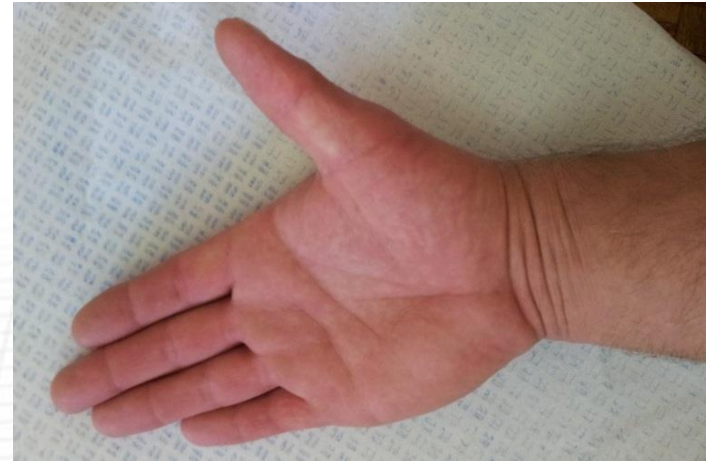
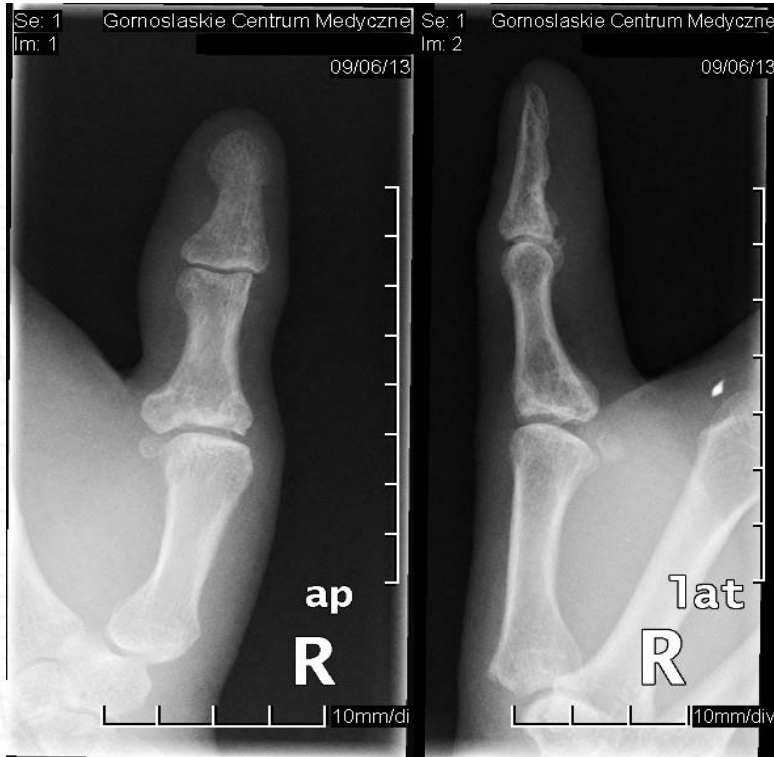## Case 2

- Male, 42 years old, explosion of gas cylinder – comminuted intra-articular fracture of right thumb (base of proximal phalanx and base of distal phalanx).



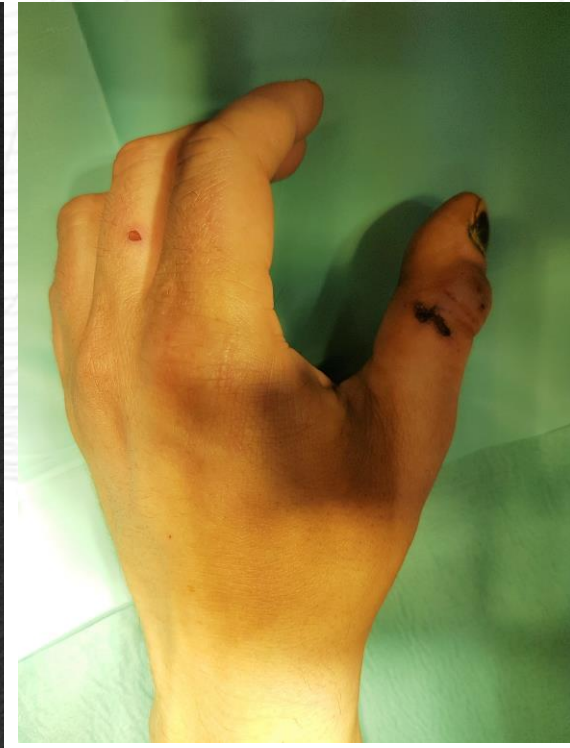
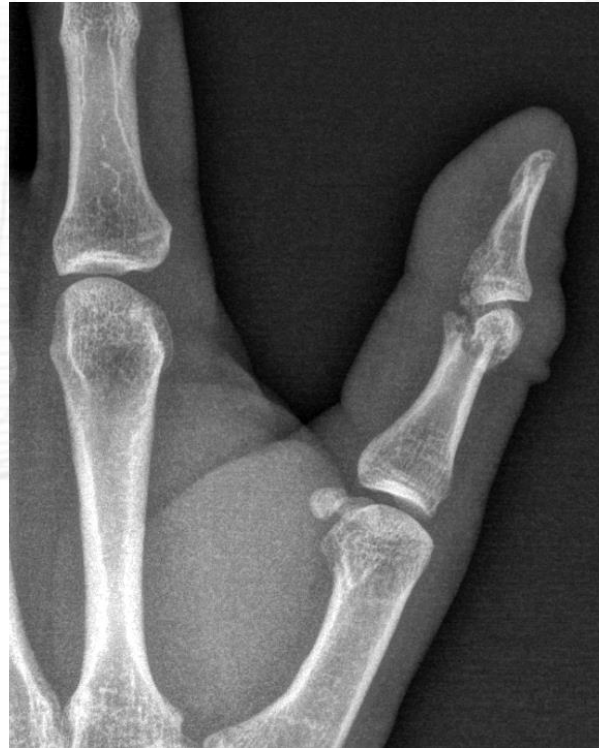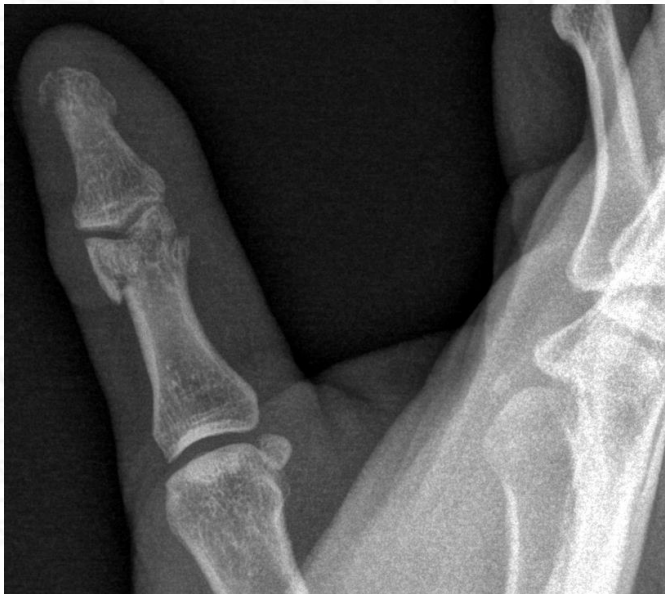## Case 2



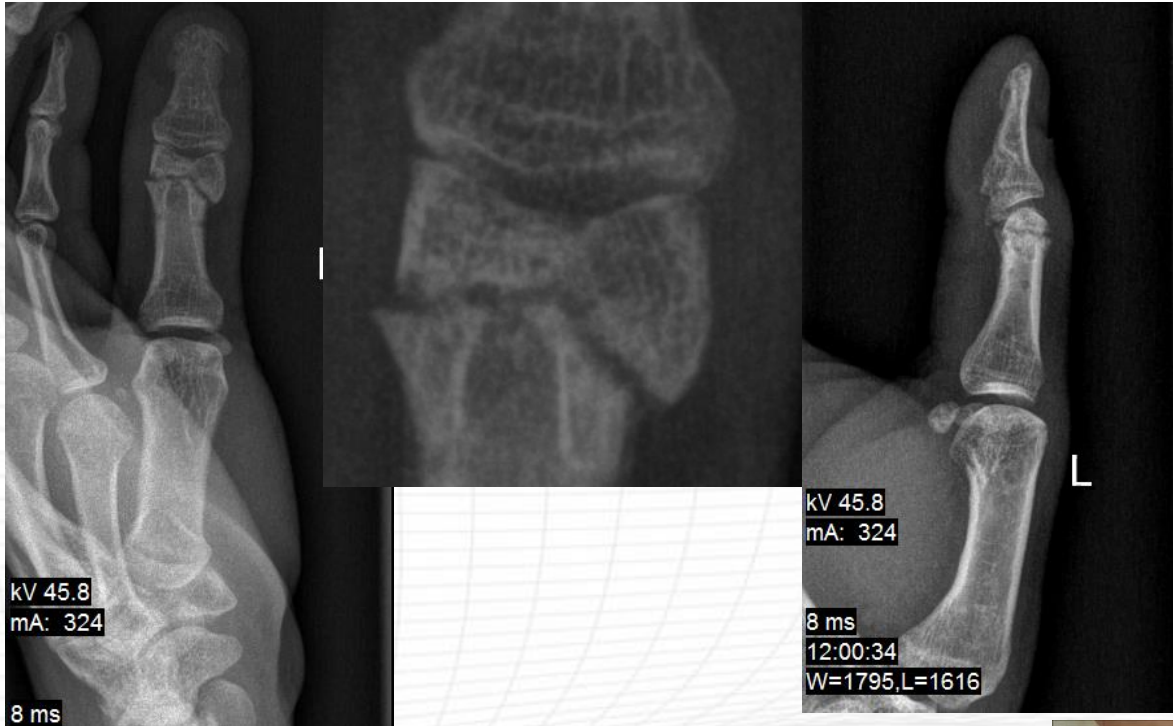
DASH questionnaire – 34 pkt.  
Kapandji test - 10

## Case 3

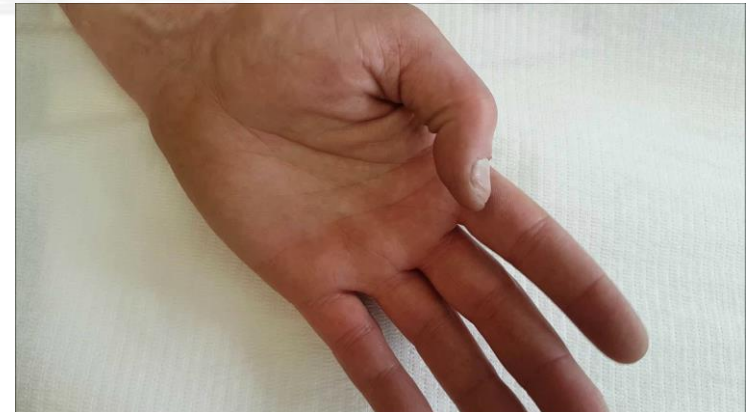- Male, 34 years old, ZOO employee, crocodile bite – comminuted intra-articular fracture of left thumb (head of proximal phalanx).



# Case 3



DASH questionnaire – 33 pkt.  
Kapandji test - 10



# Conclusions

- Dynamic distraction external fixation by Slade in comminuted, intra-articular fractures of thumb, with extensive soft tissue injuries seems to be a very good treatment option, easily available, inexpensive, and above all associated with good treatment outcomes.
- Positioning the thumb in opposition to the other fingers is very good for placement of the stabilizer, the subsequent use of the device, and acceptance by the patient.
- The disadvantage of this method seems to be imprecise control distraction force, which can affect the time of achieving the bone union, however, it does not seem to affect the final functional result of treatment.



Thank you for your attention